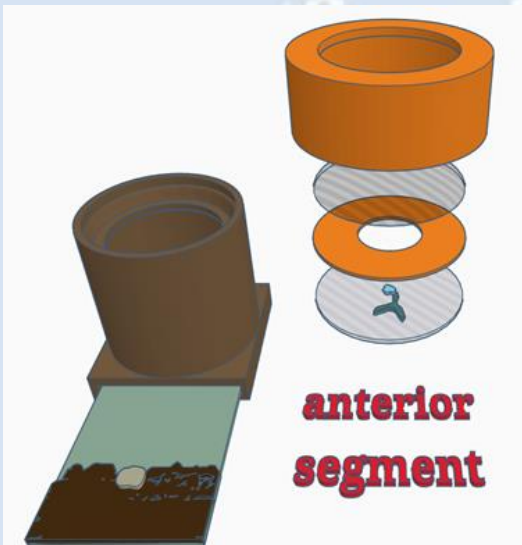


# Practical session 3: iris & lens



# Practical session 3: iris & lens

## Key skills

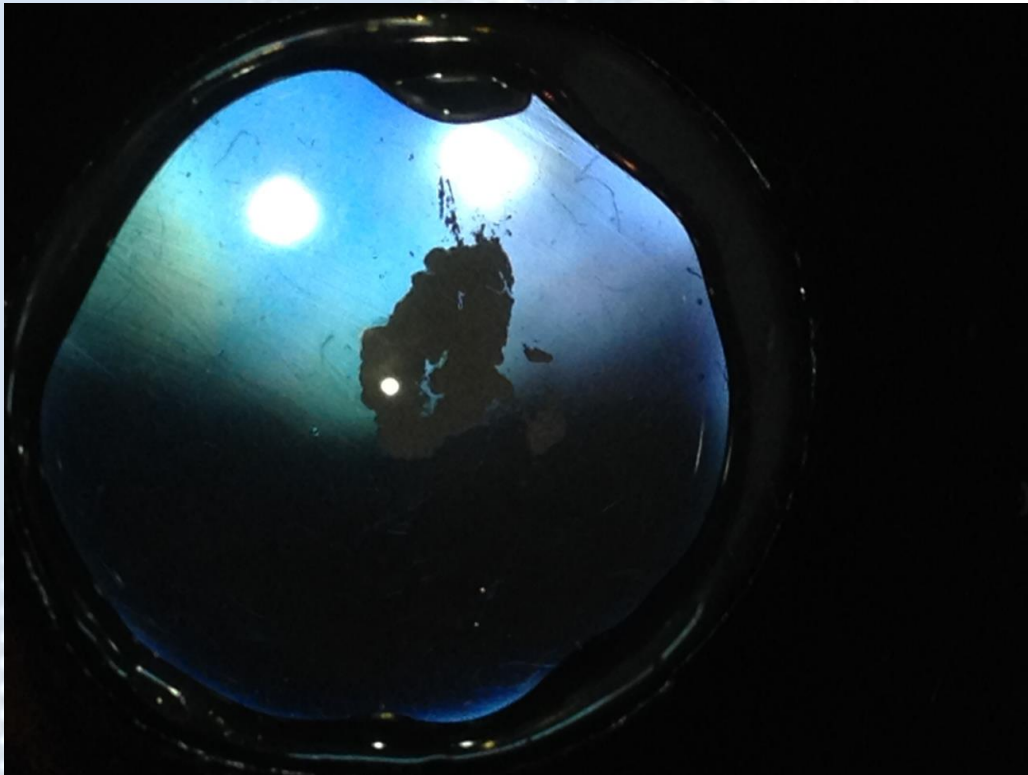
- Use DD to identify lens opacities
- Use DD to localise lesions using parallax
- Use Macro lens to obtain magnified view of iris face and anterior lens lesions using both direct (oblique broad beam) and indirect (retro illumination) lighting techniques to document lens opacities
- Use slit beam adaptor on pen torch, localise lens opacities using slit beam and image with and without the macro lens

## Equipment needed

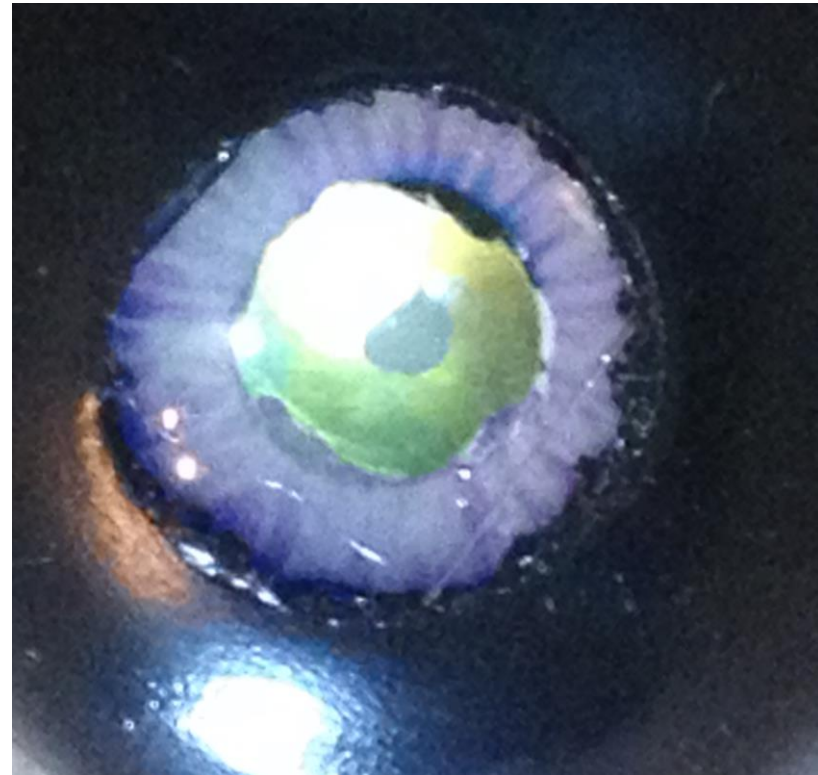
- Smart phone.
- Camera app which allows light to be in “torch mode” whilst capturing images.
- Pen torch +/- slit lamp adaptor.
- Macro lens
- Eye model set up in “anterior segment” mode. (1) simple lid (2) retinal image (3) top planoconvex lens with no opacities (4) paper iris (5) bottom planoconvex lens with painted anterior and posterior “lens” opacities.

# Task 1: Use Distant direct to identify & image lens opacities using eye model



**Distant direct at 30cm**



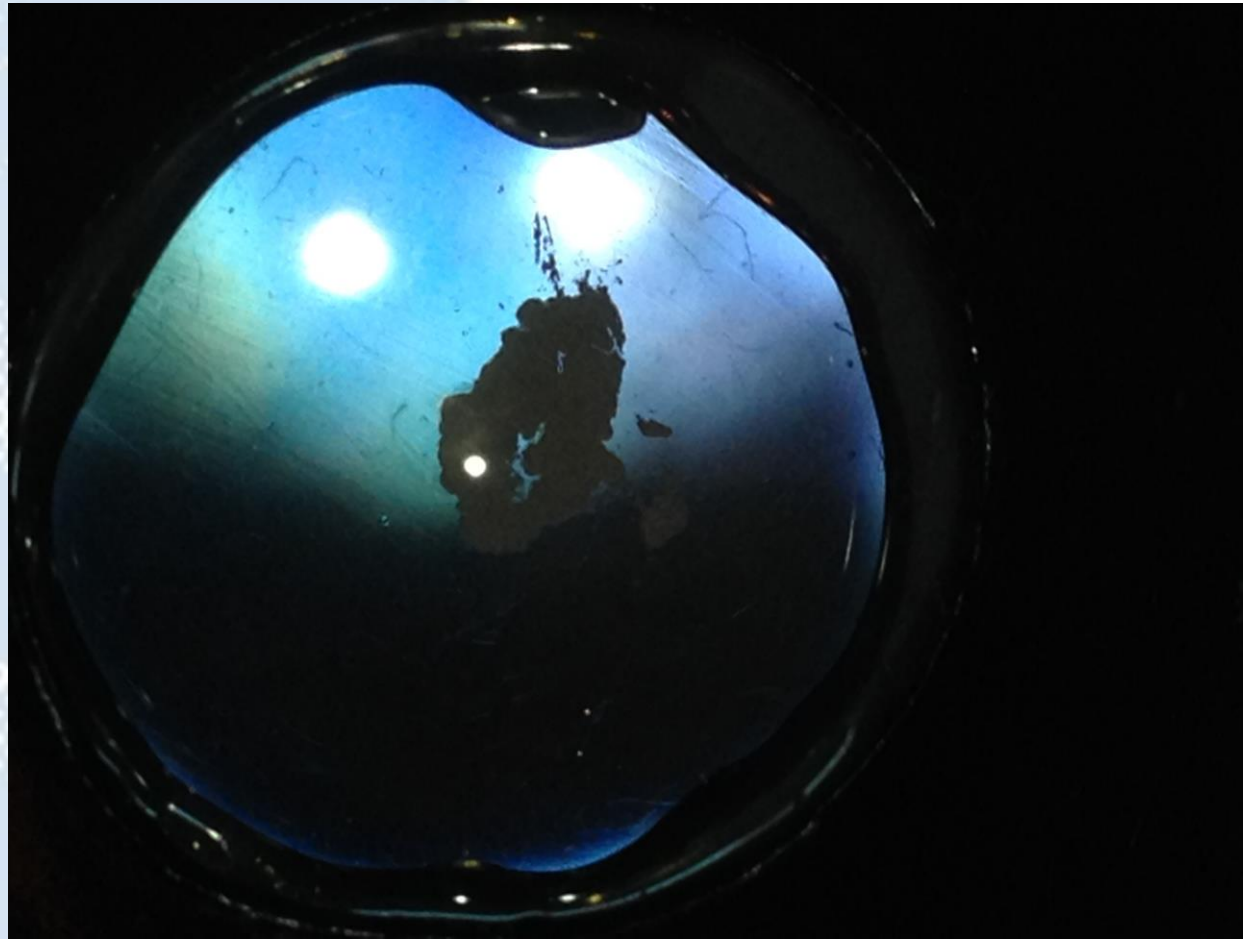
**“Close” Distant direct at 10cm**



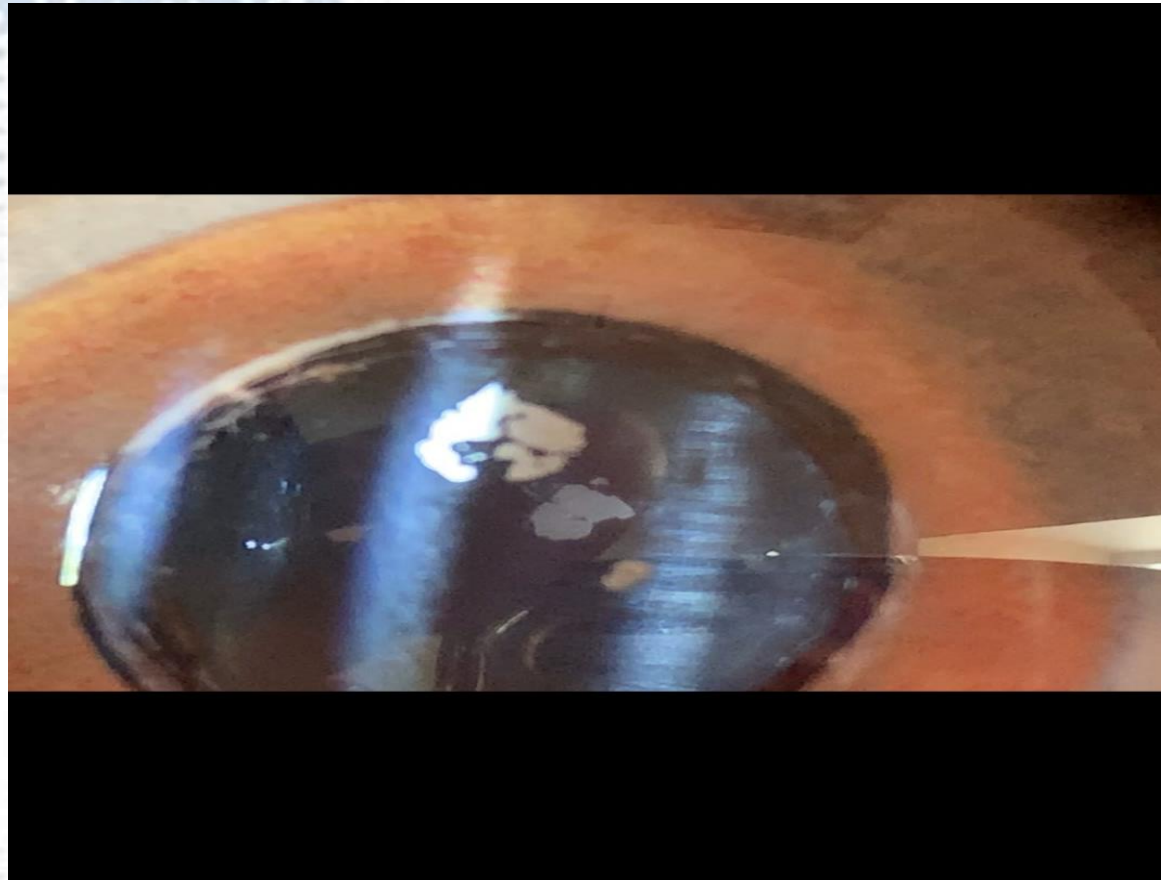# Task 2: Use macro lens to image iris and anterior lens opacity using eye model



Task 3: Use retroillumination to image the lens lesions



Task 4: Simulate slit beam illumination technique to localise and image lens lesions



Task 5: Use your new macro lens skills to image your partner's anterior chamber.

*Oblique illumination, 10x macro lens, iPhone 7plus. Post processed with HDR type filter (Camera +, "Clarity filter")*

*WhatsApp me your best image for a prize !*

*+447782219868*

