



IVC EVIDENSIA
ACADEMY
TRAINING CENTRE



IVC Graduate Academy Ophthalmic Surgery

Course notes

Tim Knott BSc BVSc (Hons) CertVOphthal MRCVS
David Nutbrown-Hughes BVSc CertVOphthal MRCVS

Rowe Referrals – Eye Clinic, Bristol

eyes@rowevetgroup.com

COURSE OVERVIEW:

Talk 1: Introduction & general principles of ophthalmic surgery

- Introduction
- Magnification
- Anaesthesia for ophthalmic patients
- Positioning
- Surgical preparation
- Instrumentation

Talk 2: Eye lid surgery

- Key anatomy
 - Eye lid function – lacrimal lake, tear film, BOS
 - The eye lid margin – tarsal plate/Meibomian glands/cilia/figure of 8 suture
 - Eye lid muscles - Orbicularis oculi/levator palpebrae
 - Eye lid attachments - Canthal tendons
- Key conditions
 - Entropion
 - Assessing the eye lids
 - Surgical techniques for repair of entropion – **tacking/lid shortening/Hotz-Celsus/Stades procedure***
 - **Temporary Tarsorrhaphy**
 - **Marginal sutures (figure of 8)**
 - **Eye lid masses (house incision)**
 - **Laceration repair (2- layer closure)**

Wet lab session 1: Eye lids

Talk 3: Nasolacrimal system inc third eye lid.

Nasolacrimal system

- Anatomy overview
- Identifying & cannulating nasolacrimal puncta

Third eye lid surgery

- Key anatomy/function
- **Third eye lid flap**
- Cherry eye*
- Scrolled third eye lid cartilage*

Wet lab session 2: Nasolacrimal system

Talk 4: Enucleation

- Key anatomy – orbital ligament, conjunctival sack
- **Trans-conjunctival enucleation**

- **Trans-palpebral enucleation**
- Proptosis of the globe

Wet lab session 3: Enucleation

*Demonstration/lecture only

Procedures in bold to be performed by delegates

INTRODUCTION TO OPHTHALMIC SURGERY

General Considerations:

- Instruments are delicate – look after them well, learn their names!
- Magnification is very helpful
- Be organised
- Drape with care
- Use 1:50 povidone iodine SOLUTION for scrubbing
- Prep for 3 minutes
- Use common sense with Elizabethan collars

Correct use of instruments and suture:

- Grip the needle correctly
- Rotate your wrist not your arm
- Place sutures accurately and evenly
- Curved needles do not pass in straight lines. Let the needle guide you. No force required.
- Practice correct knots – whatever the pattern you decide on
- Practice locking knots properly at the tension you require.

Iatrogenic KCS:

Anaesthesia

- STT can be affected for 24 hours after anaesthesia/sedation
- Effect more prolonged in anaesthesia greater than 2 hours
- lubricate and lubricate more, consider pre and post-operative lubrication in at risk dogs such as brachycephalics breeds.

Antibiotics:

- Un-necessary? – clean surgery
- Prophylactic or treatment – use cytology early and regularly. Look at yourself
- Bacteriostatic or bactericidal
- Topically don't forget they are toxic! Especially gentamicin
- Culture and sensitivity

Drug	Spectrum	Cidal/Static?	Notes
Ofloxacin	Broad	Cidal	Well tolerated, resistance emerging, 2 nd line drug
Fusidic acid	Narrow, G+ve	Static (Cidal at increase fq)	Licensed, low fq application SD-BD, may be irritant at higher fq
Gentamicin	Narrow, G-ve with some G+ cover, good activity vs Pseudomonas	Cidal	Licensed, Epitheliotoxic, Pseudomonas resistance emerges readily
Chloramphenicol	Broad but limited vs Pseudomonas	Static	Well tolerated, available in ointment and drops.
Doxycycline/ Chlortetracycline	Broad	Static	Given systemically excreted in tear film? metal chelator may have antiprotease activity. Probable immune modulation.
Cephalexin	G+ and some G- activity.	Static at low dose cidal at higher doses	Given systemically. Good soft tissue penetration

Table: summary of antibiotics commonly used in veterinary ophthalmology

LID SURGERY

Introduction

- Remember to warn that repeat surgeries may be required
- When planning surgeries keep it simple
- Develop a tool kit of simple procedures to use in combination

Techniques

TEMPORARY TARSORHAPHY SUTURE

- A useful alternative to the third eyelid flap
- May help contact lens retention
- Pass suture through the lid exiting and entering the meibomian glands

CONJUNCTIVAL BIOPSY

- Can be done conscious apply local and phenylephrine
- Lower lid is better for assessing goblet cells
- Take a strip of tissue

GENERAL POINTS FOR LID SURGEY

- Stabilisation important
- Consider chalazion clamp, use of your finger or a wooden tongue depressor

MASS EXCISION

- V vs house incisions
- Use a figure of 8 suture – correct apposition of the lid margin is vital
- Up to 25% of lid can be removed
- 1 or 2 layered closure

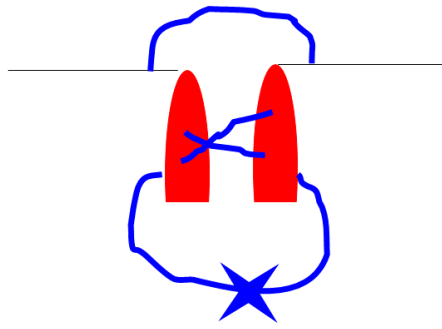


Figure of 8 suture

ENTROPION

- Plan surgery before hand
- Under rather than over correct

EYELID TACKING

- Puppies or temporary situations
- 6/0 sutures in a vertical mattress
- May need repeating

MODIFIED HOTZ-CELSUS PROCEDURE

- The aim of surgical correction of entropion should be slight under-correction. Advise clients that more than one surgery may be needed to fully correct the problem – it is easier to take more tissue away later than it is to put it back.
- Aim to remove a crescent-shaped piece of skin whose proximal edge is parallel to the lid margin.
- The initial incision is made with a number 15 scalpel blade 3-5 mm from the eyelid margin; its length depends on the amount of eyelid margin that is entropic.
- Ensure there is sufficient marginal skin to allow suturing with no risk of the sutures rubbing the cornea.
- A second elliptic incision made parallel to the first joins the two ends of the first incision. The width of the piece of tissue to be excised should have been previously determined while examining the eye with local anaesthetic applied in the non-sedated patient to determine how much eversion is required.
- The skin is undermined and excised with scissors. The defect is then closed using 4-0 to 6-0 non-absorbable suture material in a simple interrupted pattern rolling the knot away from the lid margin.

EYE LID LACERATION REPAIR

- Do not amputate any tissue – this is very vascular tissue and even sick looking tissue can recover. Removal of lid tissue may result in exposure keratitis.
 - Sample wound edge for cytological examination to guide selection of appropriate antibiotics.
 - Thorough flushing of the affected area with saline and a dilute povidone-iodine (2%) solution should be performed prior to closure
 - Use 5-0 to 6-0 absorbable suture (always use the smallest available).
 - Start with closing the eye lid margin using a figure of 8 suture
 - Close remainder of wound in 2 layers: a deep layer just beneath but not passing through the conjunctival material in a simple interrupted or simple continuous pattern starting at the eyelid margin and a superficial layer through the skin with 4-0 to 6-0 suture material in a simple interrupted pattern.
 - Lacerations of the eyelids near the medial canthus may involve the nasolacrimal apparatus and affect tear drainage. The integrity of the duct should be tested by examination of the punctae, passage of fluorescein to the nose and nasolacrimal flush if required.
 - Silicone tubing or monofilament sutures can be secured temporarily into the proximal nasolacrimal duct used to maintain patency of canaliculi following surgical repair
-

For information only

MEDIAL CANTHOPLASTY

- For brachycephalic breeds to reduce corneal exposure and resolve lower lid entropion
- Difficult surgery
- May need combination lower lid medial entropion
- Be careful to make eyes matching

LATERAL CANTHOPLASTY

- Similar technique to medial canthoplasty

STADES FORCED GRANULATION PROCEDURE

- For trichiasis in spaniels with droopy upper lids
- Useful for Sharpeis
- Difficult surgery where precision in suturing is essential
- Incision made between lashes and lid margin, all hair follicles must be removed
- Large 'half-moon' of skin excised to orbital rim region
- Skin edge sutured leaving a band of open wound to granulate along lid margin

DISTICHIASIS and ECTOPIC CILIA

- Distichiasis – often incidental
- Ectopic cilia – always significant
- Various methods to manage eg electrolysis, cryo surgery or sharp excision
- Use a chalazion clamp

WET LAB SESSION: LID SURGERY

Procedure check list - instruments:

- Identify & understand instruments
- How to use ophthalmic instruments – handling ophthalmic sutures

Procedure check list - knotting

- Suture the foam accurately using 6/0 sutures (figure of 8)
- Practice locking knots at the tensions you want
- Practice using capsized knots to adjust tension
- Double check your knotting technique

Ophthalmic anatomy check list:

- Orbital rim
- Orbital ligament
- Zygomatic arch
- Explore limits of ventral & dorsal fornix
- Pterygopalatine fossa – palpate whilst retro-pulse globe
- Medial canthal tendon
- Lateral canthal tendon
- Evert eye lid margins
- Identify the tarsal plate
- Identify Meibomian glands and their openings

Procedure check list – getting started

- Assess eye lid anatomy of your patients
- Place an eye lid clamp to facilitate examination of eye lid margins
- Practice placing eyelid speculums

Procedure check list – tacking and tarsorrhaphy

- Place temporary eversion sutures (“tacking sutures”) upper and lower lid to practice ophthalmic suturing.
- Place a temporary tarsorrhaphy – ensuring the sutures exit via Meibomian gland openings to close the eye lids.

Procedure check list – lid surgery

- Use an eye lid clamp to perform a lid shortening procedure (use a “house shaped incision to remove 5mm of lateral lower lid margin ensuring you retain tarsal plate on both sides of wound).
- Use an eye lid clamp to perform a lower lid medial Hotz-Celsus procedure.
- Eye lid laceration repair – create and repair a full thickness upper eye lid laceration which involves the eye lid margin.

Wet lab session notes

NASOLACRIMAL SYSTEM AND THIRD EYELID

Introduction

FUNCTIONS OF THE THIRD EYELID

- Secrete up to 50% of tears
- Tear spreading
- Corneal protection
- Immune function

Techniques

THIRD EYELID REMOVAL

- Do not remove unless neoplasia
- Do not remove the gland

THIRD EYELID FLAP

- TE flaps provide physical support to a weakened cornea, potentially reduce contamination of the surface of injured corneas, and minimize tear evaporation from the exposed corneas of exophthalmic globes.
- TE flaps do not allow visualisation of the cornea.
- TE flaps do not allow topical medication of the cornea.
- TE flaps do not provide plasma-derived antiproteases to melting ulcers and are not a source of collagen to replace missing corneal tissue.
- They may be indicated in superficial non-healing and non-infected corneal ulcers where compliance with topical medication is poor, in ulcers caused by facial nerve paralysis, to reinforce a corneal graft and to protect a fragile cornea during transport to a specialist centre.
- TE flaps are contraindicated for melting corneal ulcers in all species because they do not provide a blood supply or fibrovascular tissues to the ulcer. In addition, they may make it impossible to observe the progression of the disease visually, impede

the penetration of topical medications to the cornea, and cause the retention of inflammatory exudates adjacent to the corneal lesion.

- General anaesthesia is recommended for performing a TE flap although conscious surgery is possible with local anaesthesia and a compliant patient where the TEL is secured to the dorsal bulbar conjunctiva
 - One method is to secure the third eye lid to the dorsolateral bulbar conjunctiva using 2-3 mattress or cruciate sutures using a 6-0 multifilament absorbable suture.
 - Formation of a TE flap with attachment to the upper eyelid may also be performed by placing two to four horizontal mattress sutures through stents high in the upper eyelid via the dorsal fornix of the desired location. Direct the needle (4-0 suture) through the anterior face of the TE approximately 3 mm from the leading edge and then again through the fornix to the skin adjacent to the first bite. These sutures should pass through the cartilage but not be full thickness in the TE. While this technique allows the TEF to be untied and replaced, in practice this is poorly tolerated both by the patient and the fragile upper lid skin.
-

For information only

PROLAPSE OF THE NICTITANS GLAND ('CHERRY EYE')

- Never remove the third eyelid gland
- Several techniques – the pocket technique is preferred
- Gain exposure with stay sutures
- Apply phenylephrine
- Mark incisions proximal and distal to the gland – there MUST be gap between the ends of these incisions
- Suture the incisions with 6/0 suture material (authors use 'Polysorb' or 'Optime') knots must be on the palpebral side of the third eyelid
- Suture in two layers, ensuring no suture rubs the globe (suture subconjunctival tissue or use inverting suture pattern).

SCROLLING OF THIRD EYELID

- Possible genetic cause in German pointers
- Differentiate from cherry eye by identifying the eyelid margin
- Excise the abnormal cartilage or thermocautery

WET LAB SESSION: NASOLACRIMAL SYSTEM

Ophthalmic anatomy check list:

- Medial canthal pocket.
- Lacrimal lake (use Clinitas or fluorescein to form).
- Caruncle (check for caruncular hairs – could they cause wicking?).
- Prolapse third eye lid.
- Identify third eye lid cartilage.
- Evert caudal third eye lid – examine caudal surface (lymphoid follicles).
- Identify nasolacrimal punctae.
- Identify nasal ostium –good luck.

Procedure check list:

- Canulate upper and lower punctae
- Flush nasolacrimal duct
- Canulate parotid papilla
- Place stay sutures to position TEL for cherry eye repair.
- *Make conjunctival incisions in preparation for cherry eye repair (pocket technique).*
- Place third eye lid flap (use 2 mattress sutures to fix TEL to bulbar conjunctiva).
- Perform conjunctival biopsy (ventral fornix).
- *Identify and resect small section of TEL cartilage (to mimic scroll repair)*
- Continue lid surgery techniques from session 1 if wish

Wet lab session notes

ENUCLEATION

Retrobulbar block

Significant risks are associated with this technique including retrobulbar bleeding, globe rupture and injection of local anaesthetic into the blood stream or the CSF leading to sudden cardiac or respiratory arrest.

A pre-curved fine gauge $\frac{3}{4}$ " needle (23g or smaller) is passed either sub-conjunctivally or through the eye lid aiming to run the needle close to the globe prior to slow injection of local anaesthetic in the immediate retrobulbar space. Care should be taken to draw back prior to injection. An entry point dorsolateral to the globe is preferred.

Try this technique at least once using 1ml of ink prior to enucleation.

This technique can provide excellent postoperative analgesia however careful and considerate dissection and the use of a retrobulbar splash block prior to closure can also provide excellent analgesia also

Enucleation Techniques

Two approaches are described, the transpalpebral and subconjunctival techniques..

Regardless of technique the aims should be to:

- Use appropriate instruments.
- Use clean kit to close when infection or neoplasia suspected.
- Surgically prepare both the skin and the ocular surfaces (including the conjunctival fornices).
- Remove all conjunctival tissue.
- Stay as close to the globe and the conjunctival sac as possible.

- Remove the minimum amount of tissue.
- Identify and section the extra-ocular muscles at their insertion.
- Maintain the globe's integrity.
- Avoid tractional forces on globe prior to section of optic nerve head (especially in cats)
- Avoid clamping optic nerve (especially in cats).
- Section the optic nerve leaving a small section attached to the globe.
- Ensure the orbit is not contaminated during surgery. Irrigate with warm saline prior to closure.
- Ensure adequate analgesia (consider retrobulbar splash block post enucleation or retrobulbar block prior to enucleation).
- Always send for histology or retain so that can.
- Close the orbital opening using the remnants of the orbital ligament. (consider the use of a non-absorbable suture to limit orbital sinking).
- Close the skin wound so that primary intention healing occurs.
- Consider the use of a short-term postoperative stent to reduce post-operative swelling and epistaxis.

Trans palpebral technique

This technique makes the eye lid dissection easier due to the support of the globe and orbital tissues and is the author's preference. Where conjunctival sac pathology, corneal and or globe infection or neoplasia is suspected this technique is preferred as it allows the conjunctival sac and globe to be removed as one structure limiting orbital contamination.

The eye lids can be sutured together or held with tissue forceps where significant risk of contamination exists however this makes dissection of the conjunctival sac more difficult.

- 1- Skin incisions are made parallel to the eye lid margins at the proximal edge of the tarsal plate (approx. 5mm from the lid margin.) using a number 15 blade.
- 2- These incisions are joined laterally and medially ensuring the caruncle and medial canthus are included.
- 3- These incisions are directed perpendicularly to the skin and extended by gentle stroking with a blade or blunt dissection until the inner surface of the conjunctiva is identified.
- 4- The direction of dissection is now altered to lie flat to the conjunctival surface.
- 5- The sub conjunctival tissue plane is identified and followed using gentle blunt dissection until the limbus is reached.
- 6- Check the depth of dissection regularly by looking inside the conjunctival sac – your scissors should be easily visible through the conjunctiva.
- 7- Once the limbus is reached the dissection is continued until the you have reached the limbus through it's entire circumference.
- 8- Grasping the free edge of the third eye lid and applying gentle traction will facilitate this dissection ventromedially.
- 9- Starting at the dorsal limbus dissect through the epibulbar fascia until the sclera is reached.
- 10- Staying as close to the sclera as possible dissect caudally until the insertion of the dorsal rectus muscle is *identified.
- 11- Placing one scissor blade under the rectus muscle insertion pull gently upwards and section the insertion immediately adjacent to the sclera.
- 12- Repeat for the other rectus and oblique muscles.
- 13- Once sectioned the globe should rotate freely.
- 14- Open your tenotomy scissors, slide curved blades caudal to the pole of the globe, push gently downwards to push the retrobulbar tissue prior to sectioning the optic nerve.
- 15- Free any remaining attachments to the globe prior to removal.

- 16- Check conjunctival sac for holes and explore orbit to remove conjunctival remnants if required.
- 17- Place a swab tightly into the orbit to halt any orbital tissue ooze.
- 18- Remove swab.
- 19- Identify the orbital ligament remnants.
- 20- Close the orbital opening using a continuous suture to bring the dorsal and ventral edges of the orbital ligament together.
- 21- Close the subcutis.
- 22- Close the skin.

Sub-conjunctival enucleation technique

In this technique the globe is removed prior to the lids and the conjunctival sac.

Haemorrhage following globe removal can make identification of the conjunctival sac more difficult and great care needs to be taken to ensure all conjunctiva is removed.

- 1- The eye lid skin incisions are easier to make if performed before the globe is removed Follow point 1-3 above.
- 2- The conjunctiva is incised 2-3 mm from the limbus for 360 degrees using a number 15 blade or sharp bladed scissors.
- 3- The extraocular muscles are identified and sectioned, the optic nerve transected and the globe removed as in points 9-15 above.
- 4- Once the globe is removed the third eye lid margin is pulled gently upwards and held with forceps prior to dissection of the conjunctival sac.
- 5- The conjunctiva is dissected as close to the conjunctiva as possible until the eye lid skin incisions are reached and the conjunctival sac and eye lid margins removed and the dissected sac checked for missing conjunctival tissue.
- 6- Closure as above.

Top tips:

- Expect some blood particularly when very inflamed or glaucomatous globes however always aim to minimise by careful dissection – aim to use 1 swab!
- We prefer not to suture eyelids shut if no significant fornix pathology
- Dissect down to a small section of conjunctiva then blunt dissect along this plane of tissue.
- It is possible to use a blade for the entire dissection by pulling gently on the conjunctival sac and stroking the sub conjunctival tissue.
- Topical phenylephrine helps conjunctival haemorrhage
- Consider stent post op.

WET LAB SESSION: ENUCLEATION

Ophthalmic anatomy check list:

Orbital septum – palpate, identify limits.

Orbital rim – palpate, identify limits.

Orbital ligament – palpate, identify limits.

The conjunctival sac– explore using a cotton bud, identify limits

Procedure check list:

- Perform retrobulbar nerve block using ink provided.
- Transpalpebral enucleation
- Transconjunctival enucleation.

Wet lab session notes