

# Third eyelid and lacrimal surgery

David Nutbrown-Hughes BVSc CertVOphthal MRCVS  
Rowe Referrals – Eye Clinic, Bristol

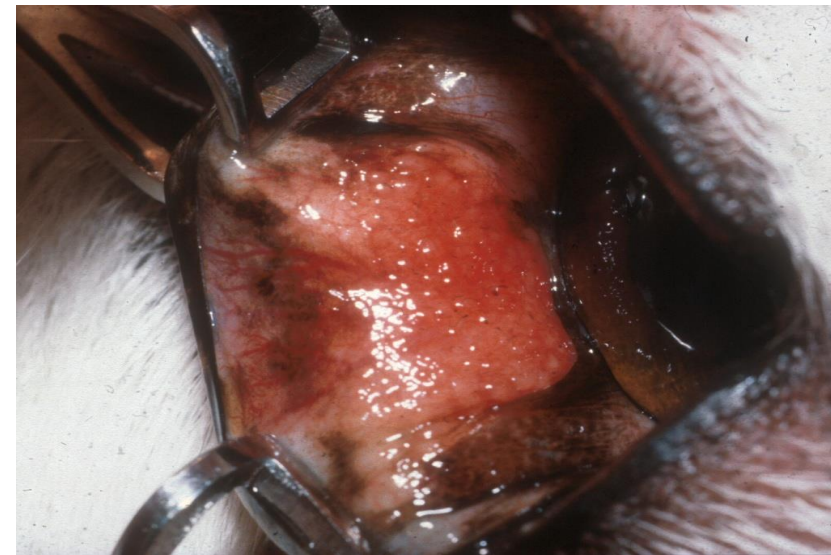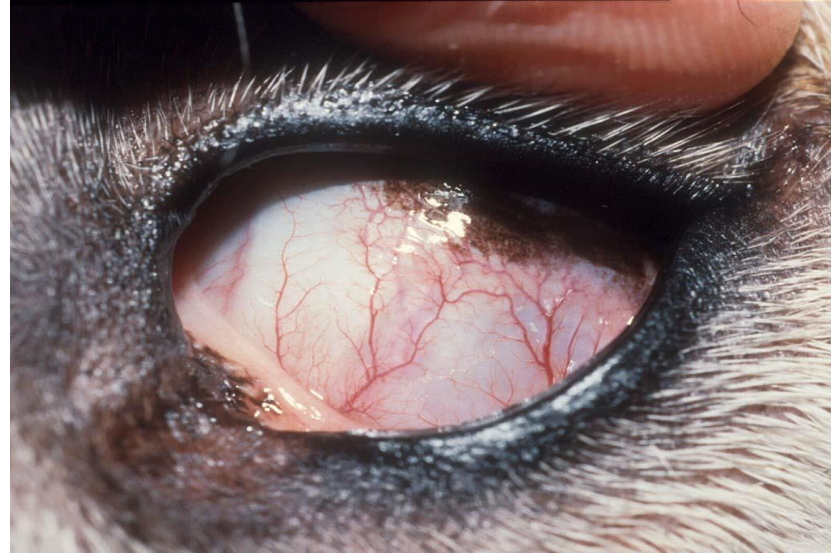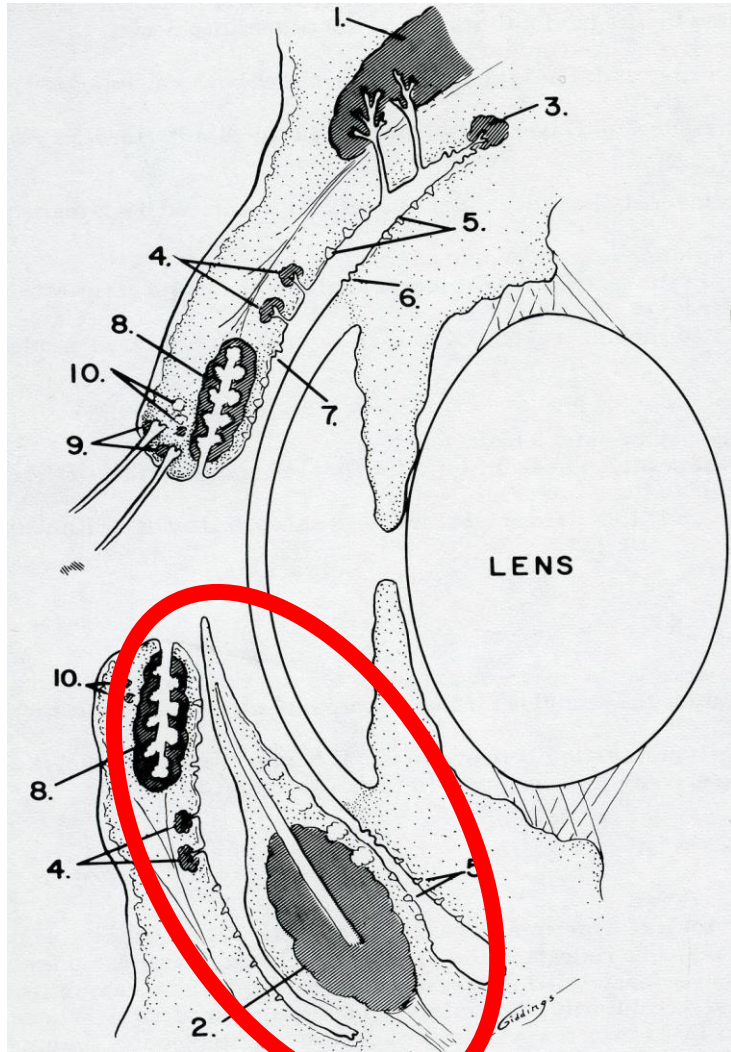
[eyes@rowevetgroup.com](mailto:eyes@rowevetgroup.com)







Cherry Eye



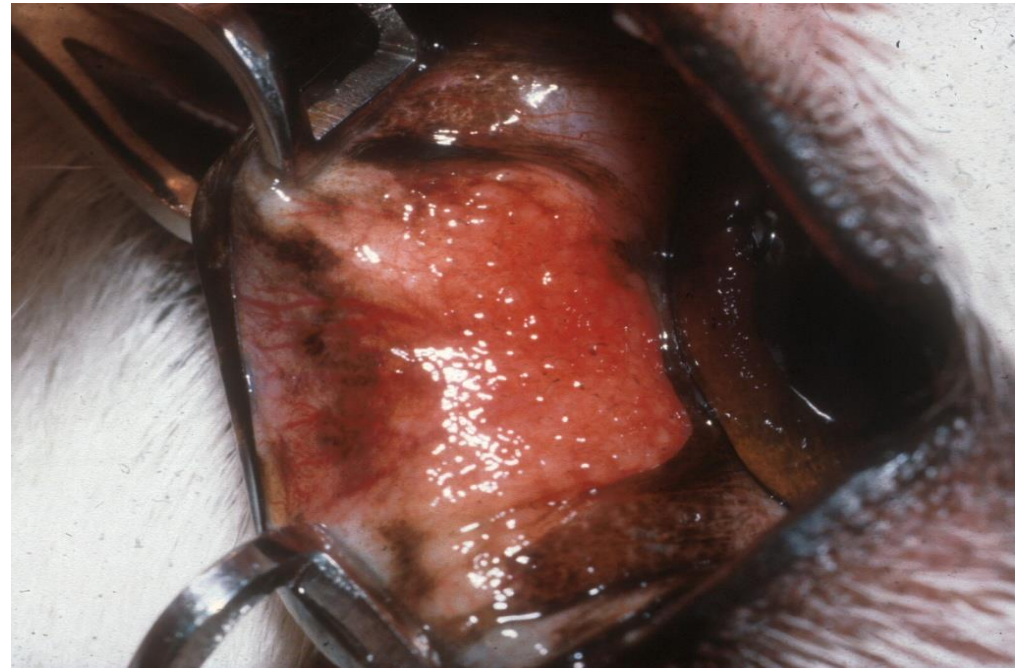
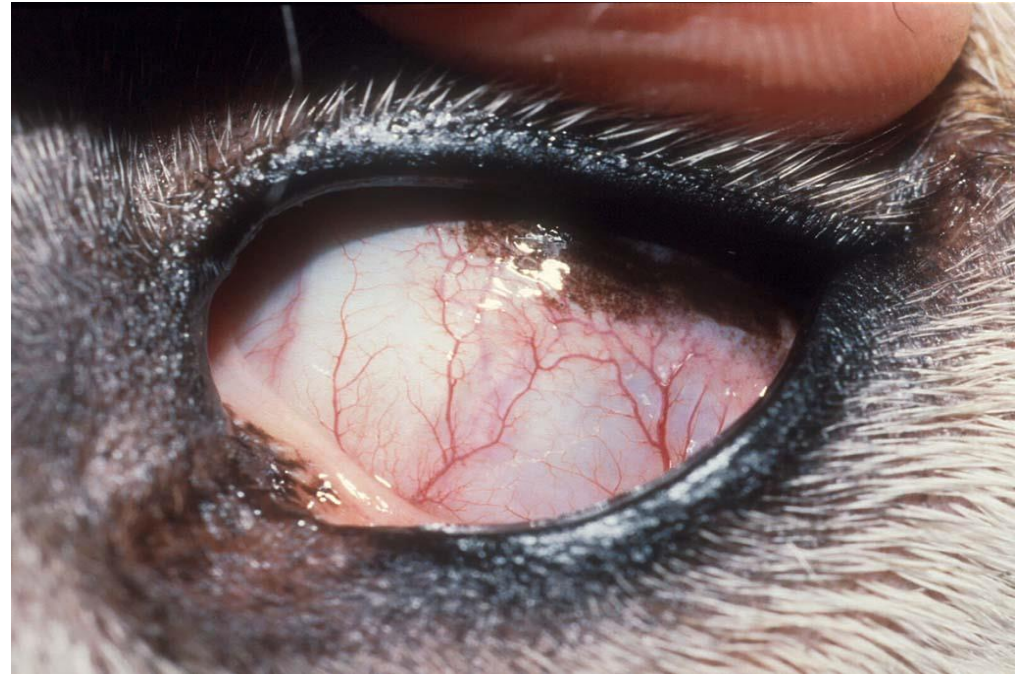# functions

Secrete up  
to 50% of  
tears

Tear  
spreading

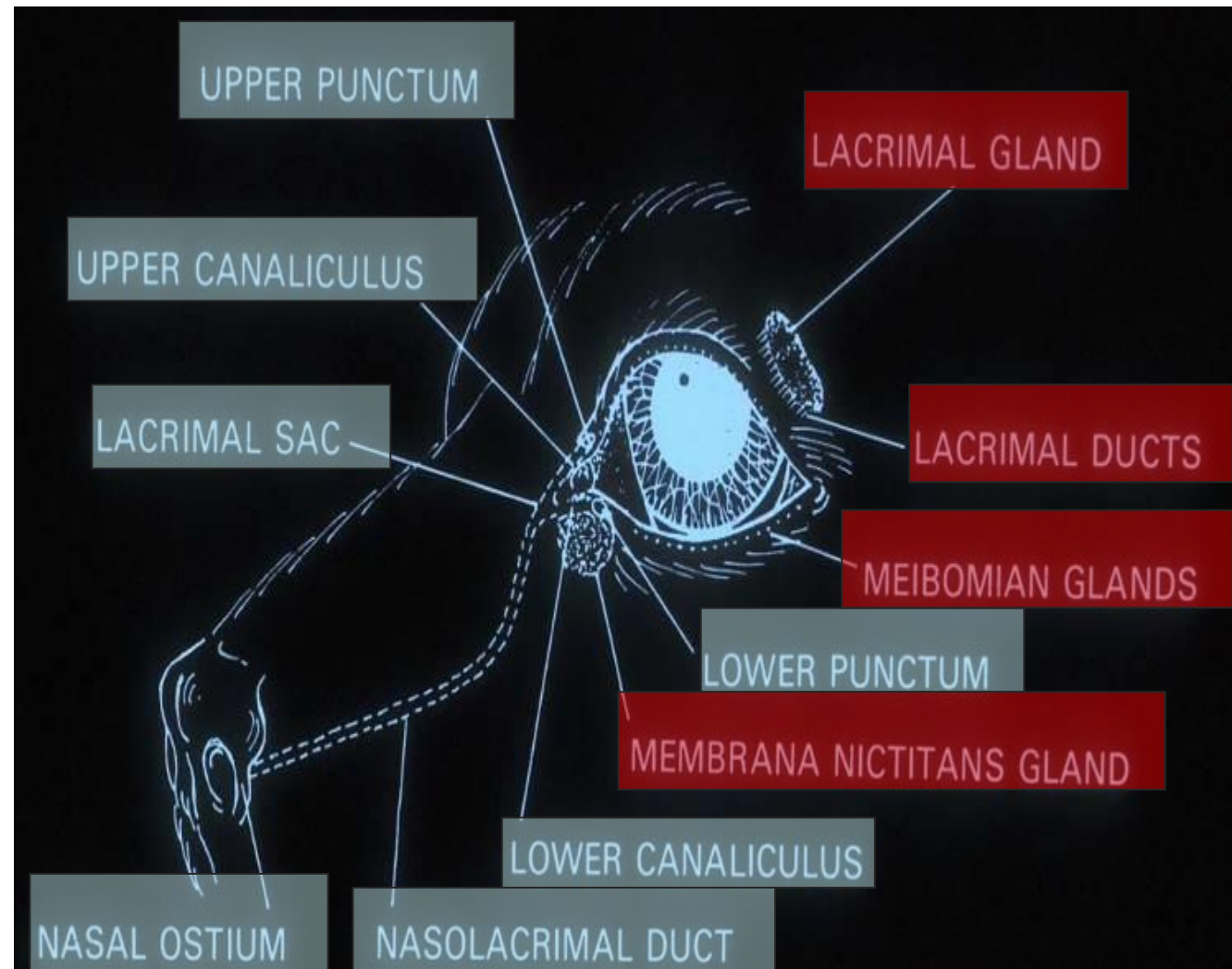
Corneal  
protection

Immune  
function



# The lacrimal system

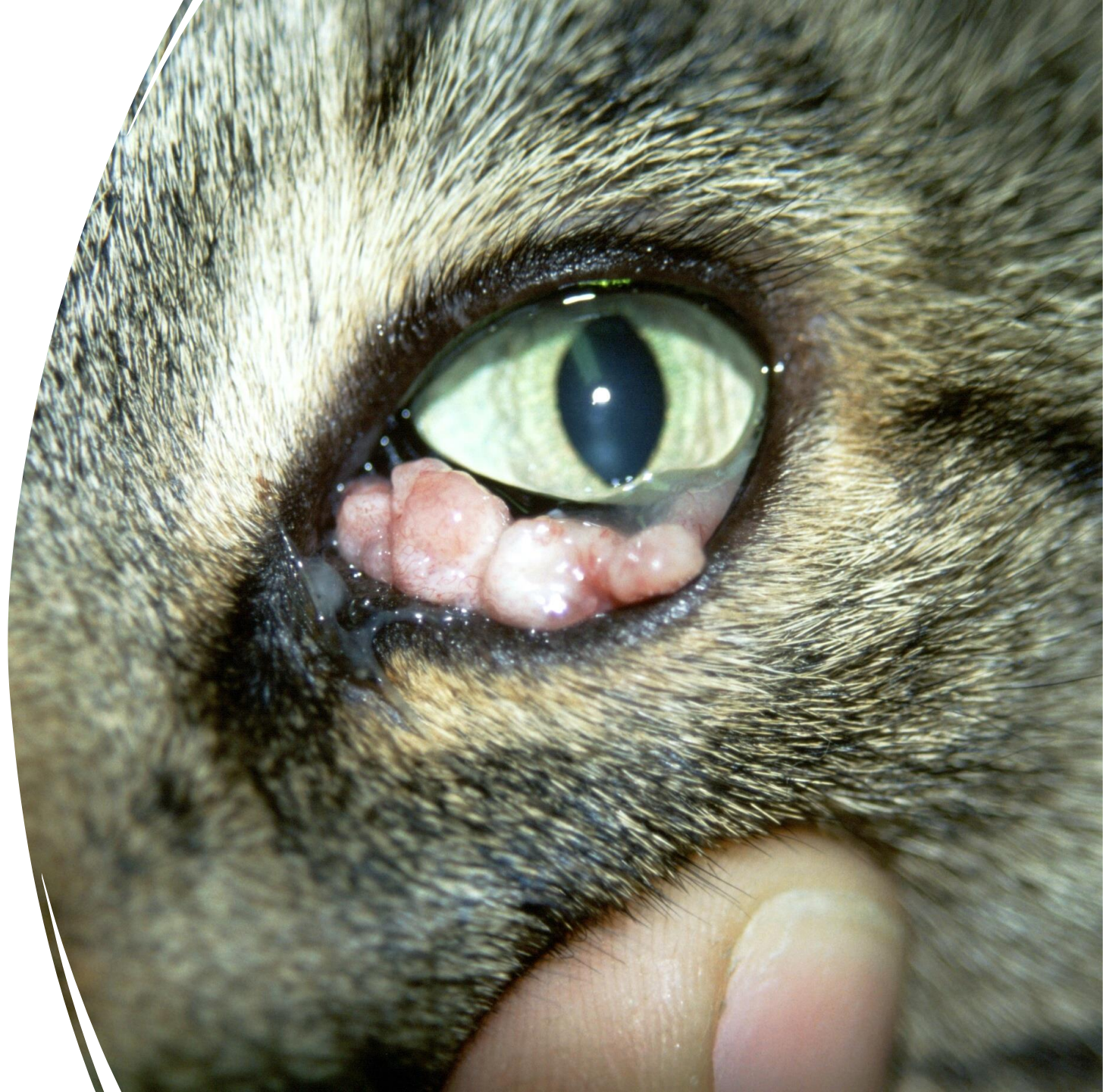- Production
- Drainage



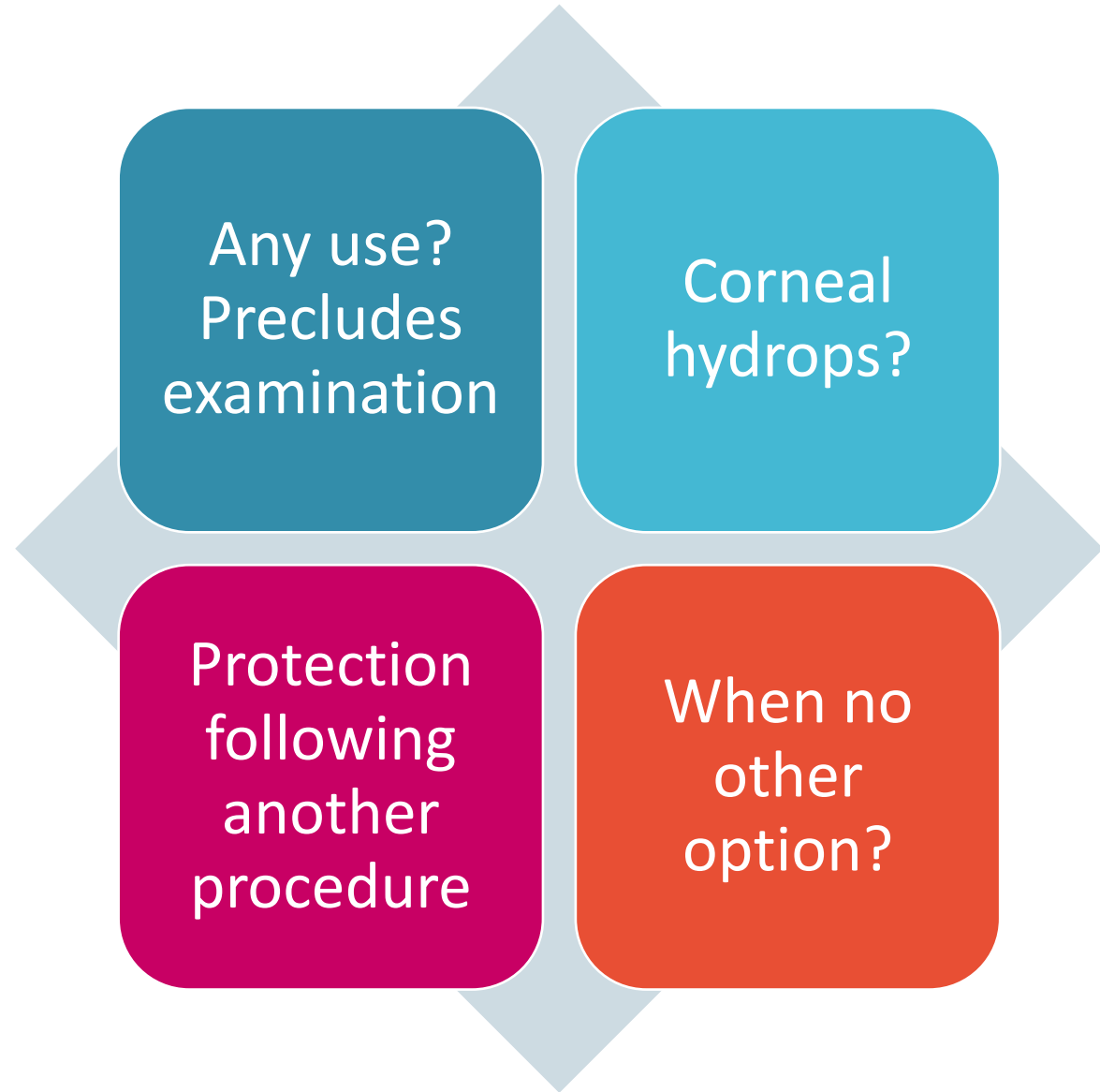
# TEL removal ?

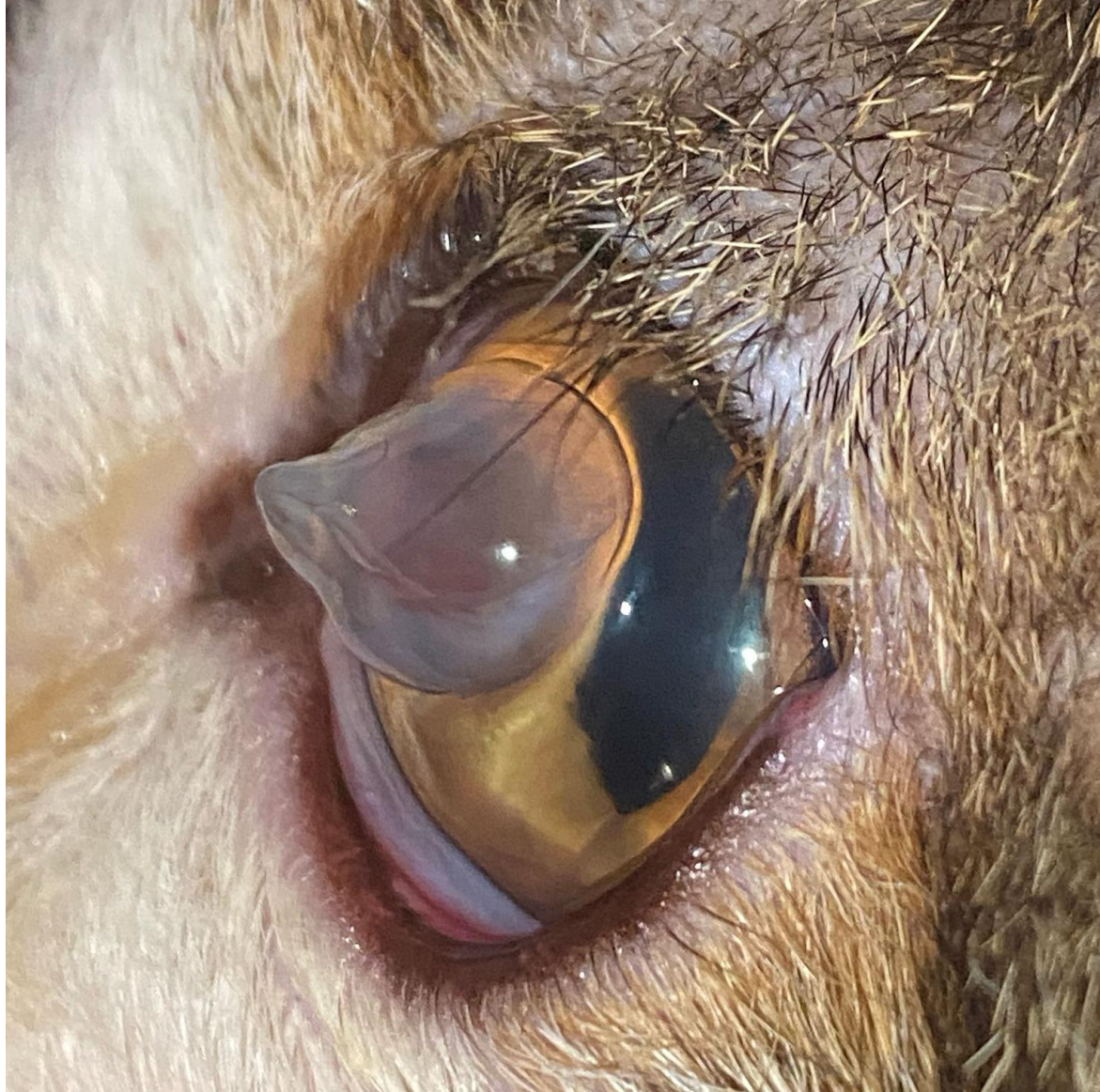---

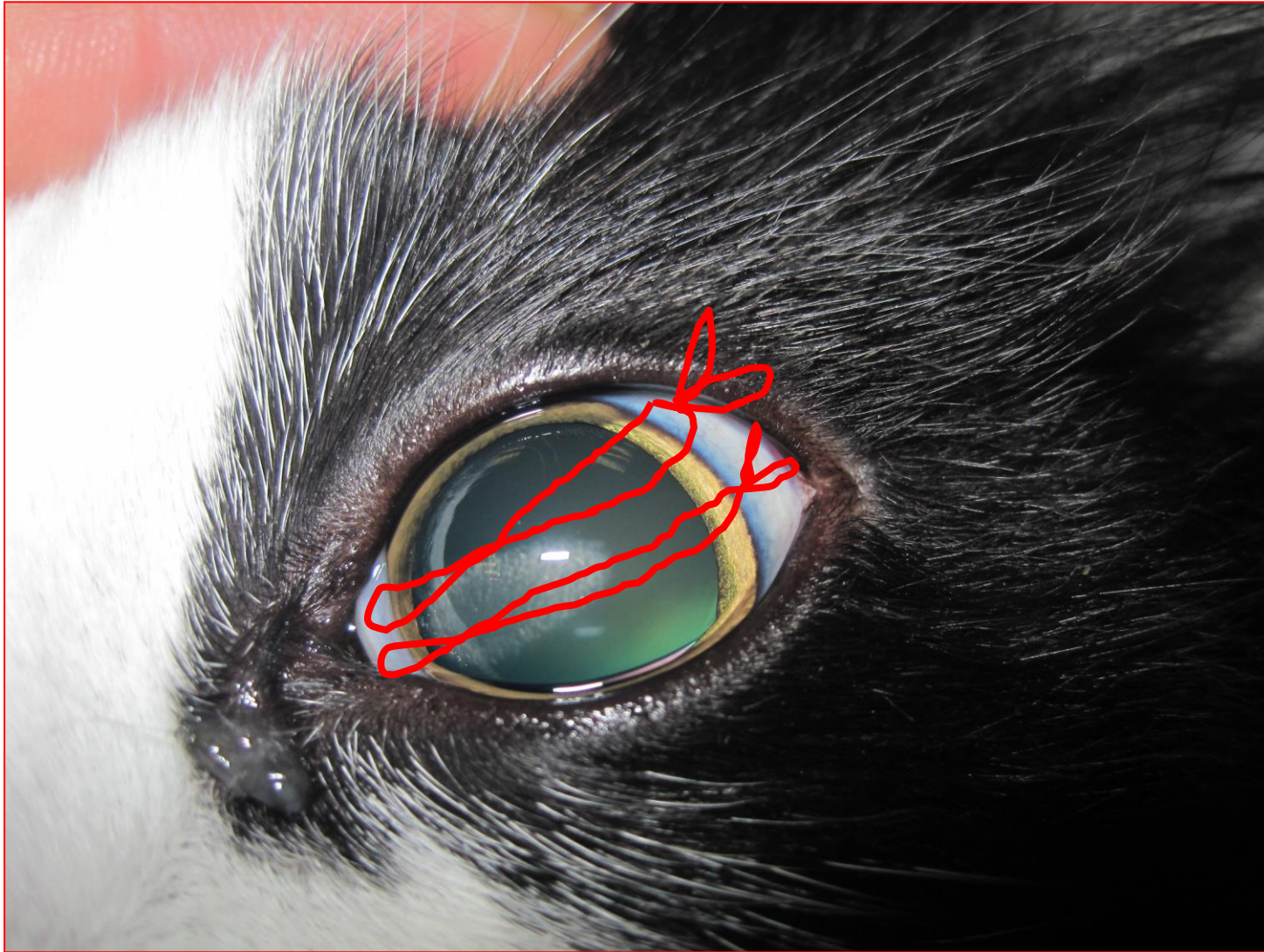
- Do not remove the third eyelid gland in cases of cherry eye !
- Only remove if neoplasia



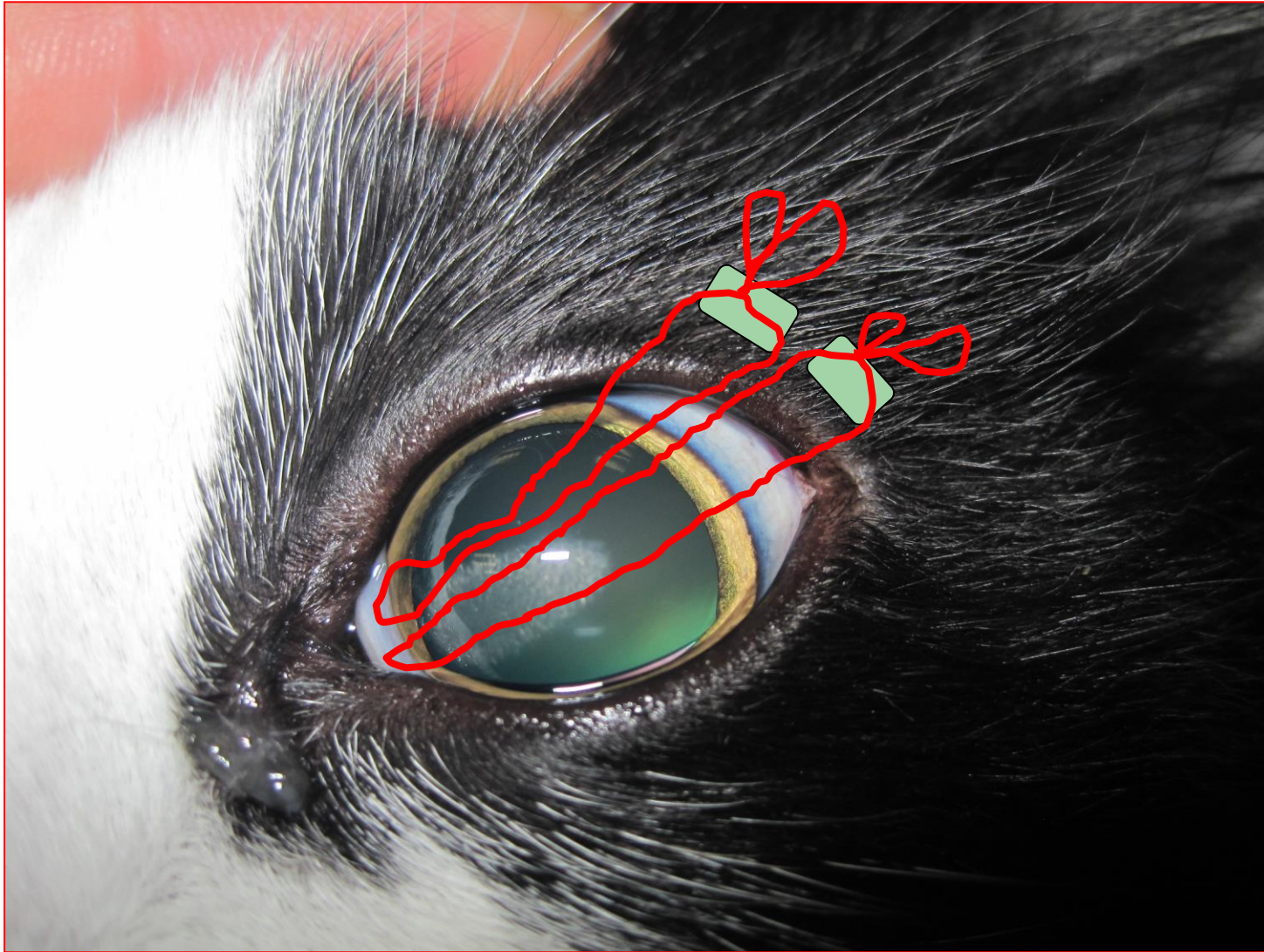
# TEL flaps







TEL flaps –  
to conj



TEL flaps –  
to lid



# Third eyelid and lacrimal surgery workshop

David Nutbrown-Hughes BVSc CertVOphthal MRCVS  
Rowe Referrals – Eye Clinic, Bristol

[eyes@rowevetgroup.com](mailto:eyes@rowevetgroup.com)

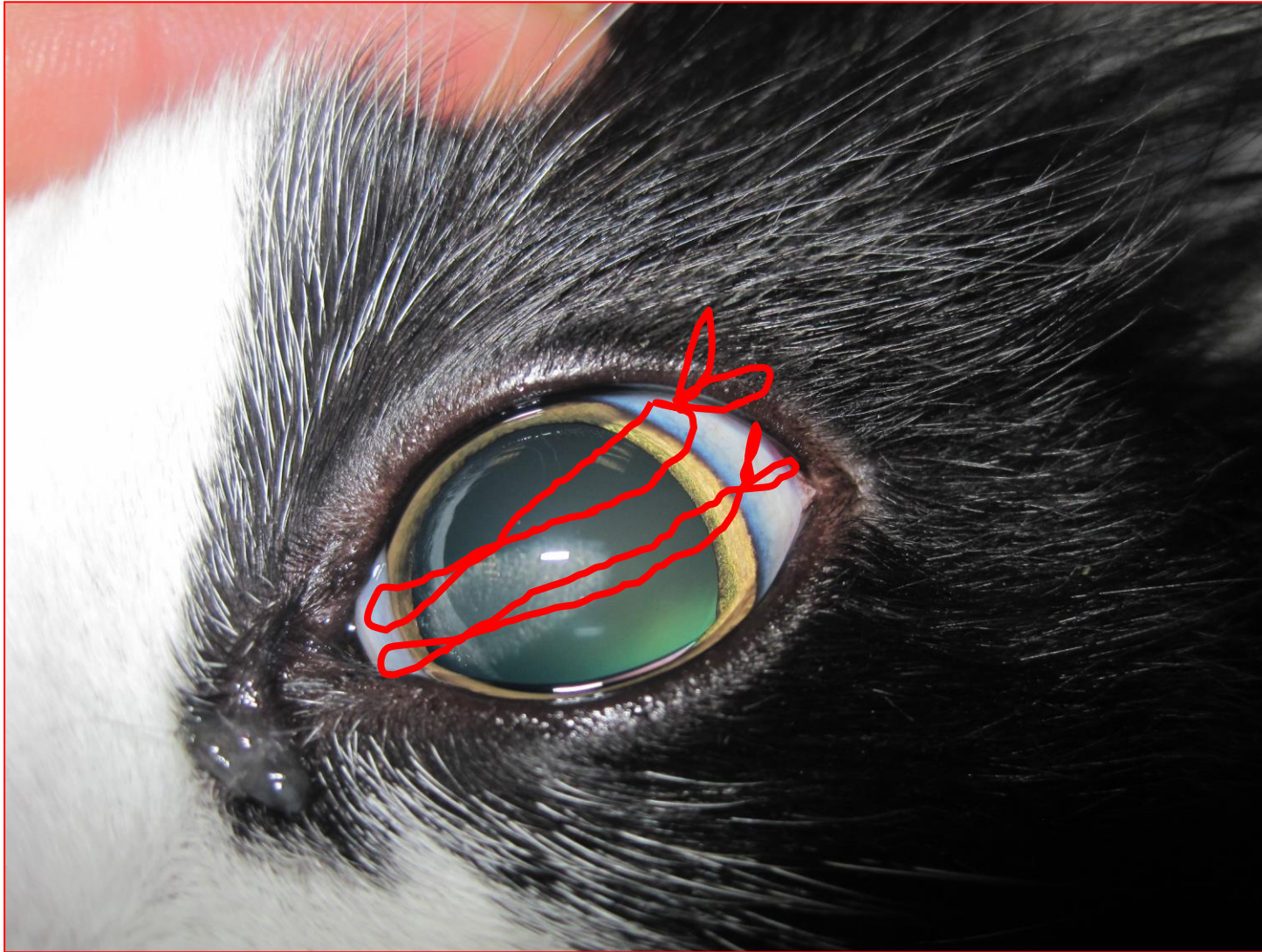


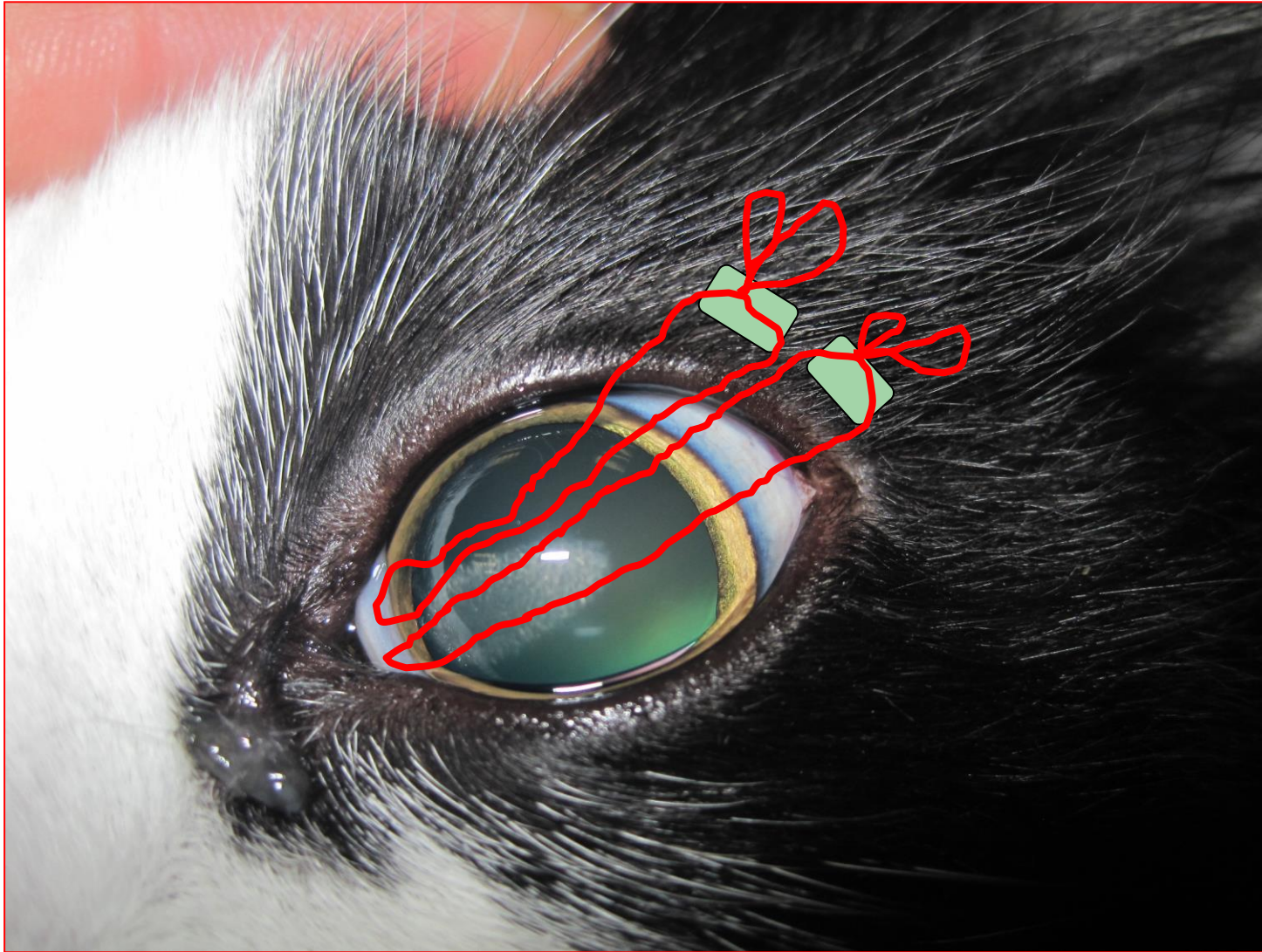
## Ophthalmic anatomy check list:

- Medial canthal pocket.
- Lacrimal lake (use Clinitas or fluorescein to form).
- Caruncle (check for caruncular hairs – could they cause wicking?).
- Prolapse third eye lid.
- Identify third eye lid cartilage.
- Evert caudal third eye lid – examine caudal surface (lymphoid follicles).
- Identify nasolacrimal punctae.
- Identify nasal ostium –good luck

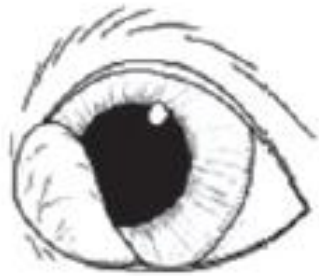## Procedure check list:

- Canulate upper and lower punctae
- Flush nasolacrimal duct
- Place third eye lid flap (use 2 mattress sutures to fix TEL to bulbar conjunctiva).
- Perform conjunctival biopsy (ventral fornix).
- Cherry eye repair
- Continue lid surgery techniques from session 1 if wish

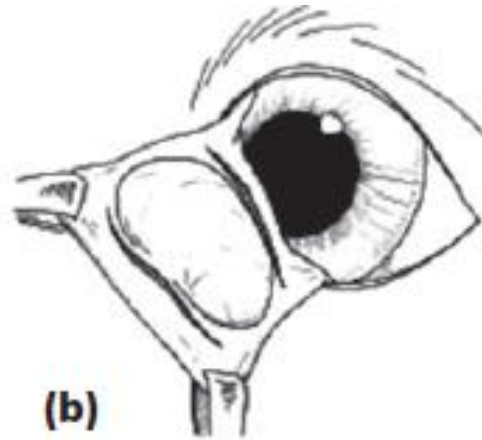




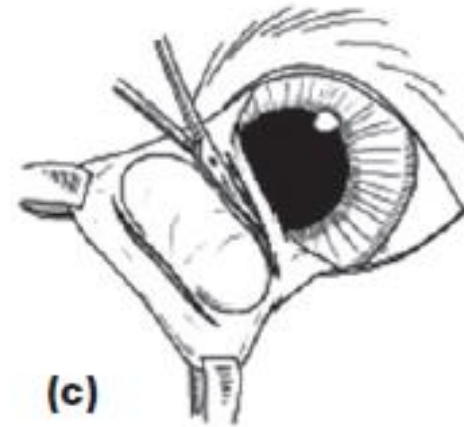
# Pocket technique for prolapsed third eye lid glands



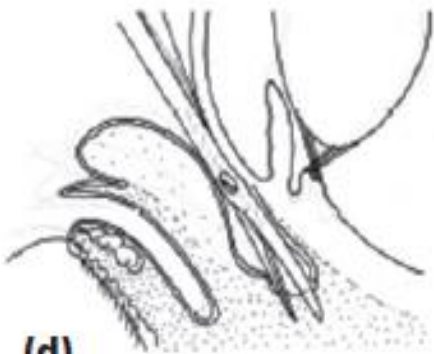(a)



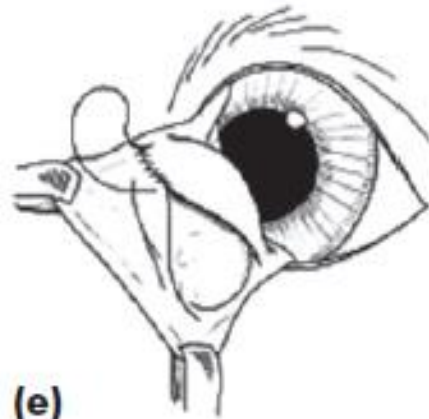
(b)



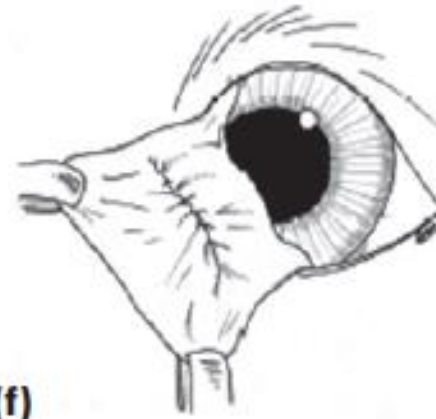
(c)



(d)



(e)



(f)

eyes@rowevetgroup.com  
01454 521000

Rowe  
Referrals



eyes@rowevetgroup.com  
01454 521000

Rowe  
Referrals

